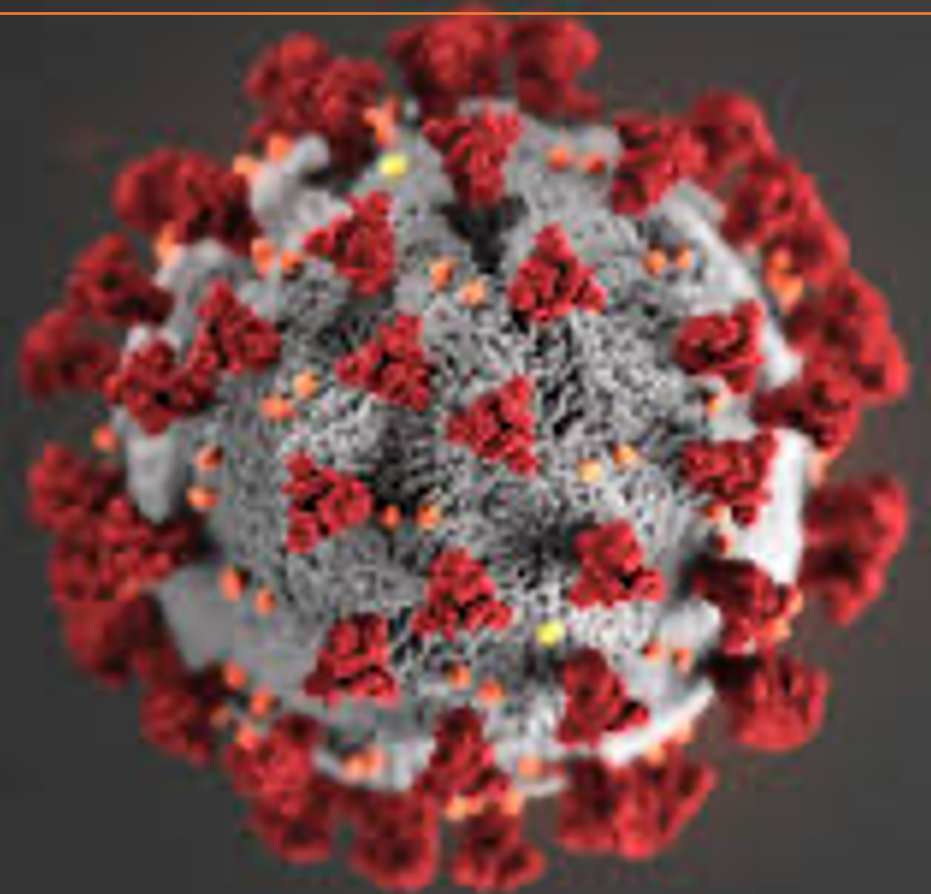


COVID-19: natural history & thrombotic risk 7th July 2020

Prof Beverley Hunt OBE

@bhwords

Guys & St Thomas Trust/ Kings Healthcare
partners , London, UK

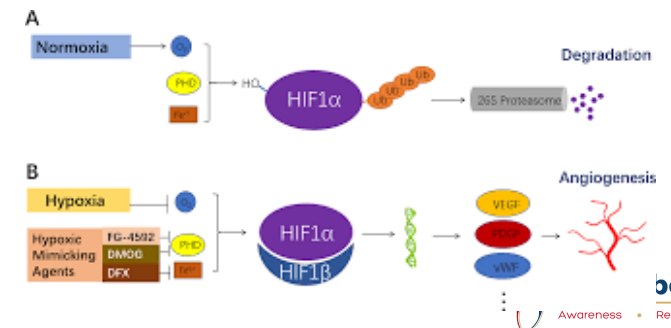
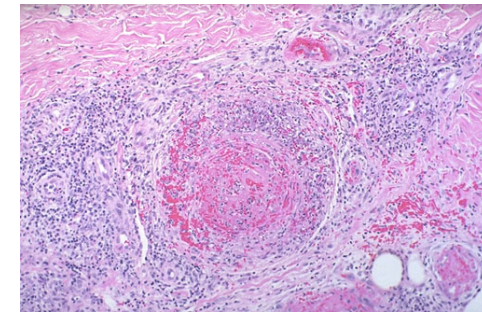
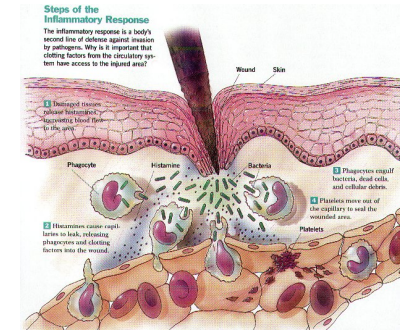


A reminder of concepts around haemostasis in sepsis, inflammation & hypoxia

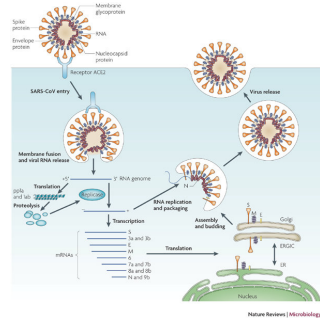

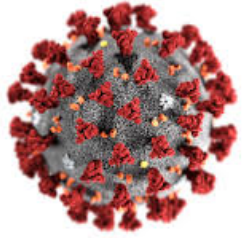
The coagulation system evolved as an effector pathway of the immune response: laying down fibrin around bacteria to physically entrap them & prevent their dissemination

Thus the end point of inflammation is thrombosis
e.g Behcets disease, vasculitis
...and anticoagulants do not improve outcome in these states
Instead we treat the inflammatory process

Hypoxia → hypoxia- inducible transcription factors which leads to a prothrombotic state (affect tissue factor & PAI-1 genes)

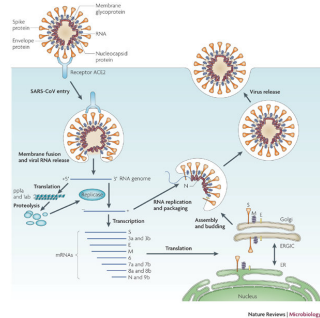

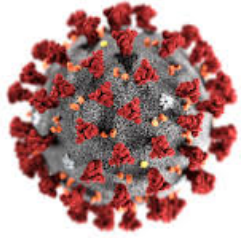


COVID-19 pathogenesis



ACE2 receptor on
Pulmonary epithelium
& endothelium

COVID-19 pathogenesis



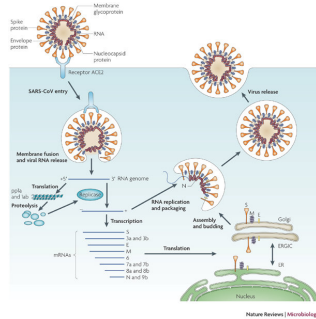

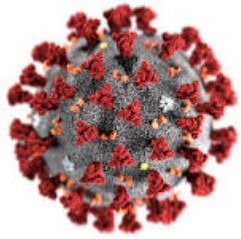
Asymptomatic
Minor infection
7-10 days fever &/or flu-like symptoms
anosmia

ACE2 receptor on
Pulmonary epithelium
& endothelium



WORLD THROMBOSIS DAY
13 OCTOBER

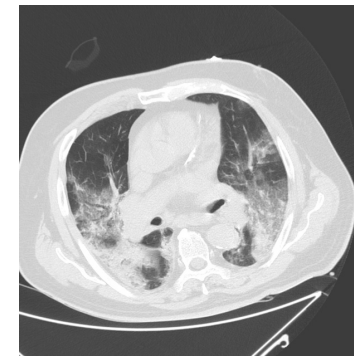
COVID-19 pathogenesis



Asymptomatic
Minor infection
7-10 days fever &/or flu-like symptoms
anosmia



In a minority (5%)
COVID-19 pneumonia
Massive inflammatory response
Cytokine storm/macrophage activation

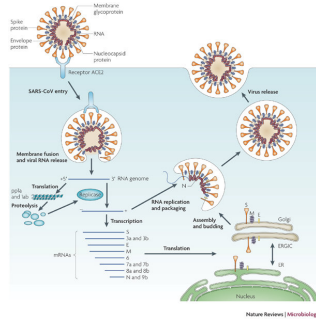

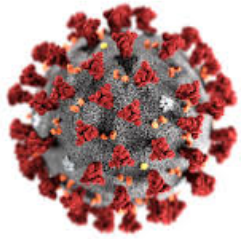


ACE2 receptor on
Pulmonary epithelium
& endothelium



WORLD THROMBOSIS DAY
13 OCTOBER


COVID-19 pathogenesis



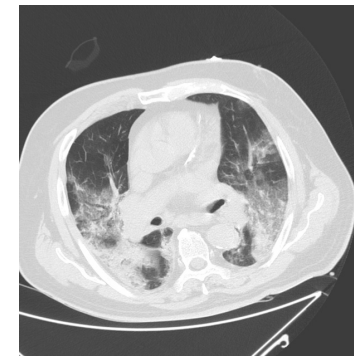
ACE2 receptor on
Pulmonary epithelium
& endothelium



Asymptomatic
Minor infection
7-10 days fever &/or flu-like symptoms
anosmia



In a minority (5%)
COVID-19 pneumonia
Massive inflammatory response
Cytokine storm/macrophage activation



Moderate
(needs O2)

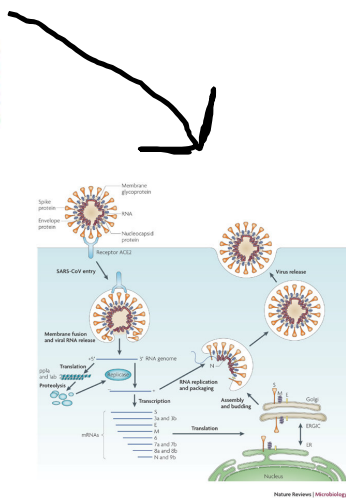
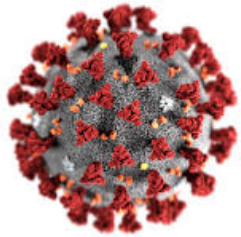


Severe
(needs mechanical
Ventilation)



WORLD THROMBOSIS DAY
13 OCTOBER

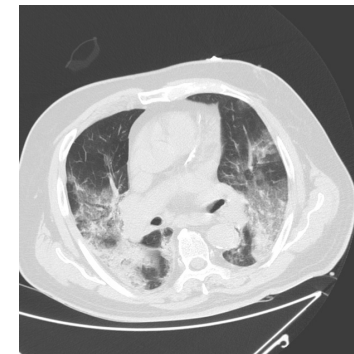
COVID-19 pathogenesis



ACE2 receptor on
Pulmonary epithelium
& endothelium

Asymptomatic
Minor infection
7-10 days fever &/or flu-like symptoms
anosmia

In a minority (5%)
COVID-19 pneumonia
Massive inflammatory response
Cytokine storm/macrophage activation

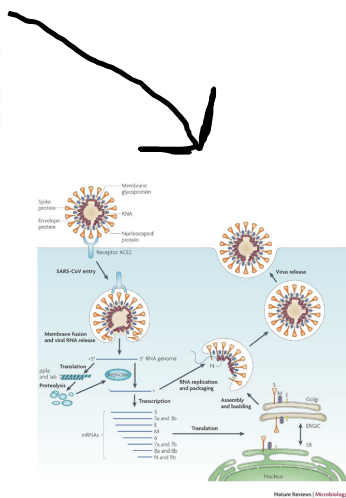
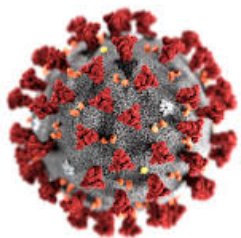


Moderate
(needs O2)

Severe
(needs mechanical
Ventilation)

Prothrombotic state due to effects of IL1, IL-6

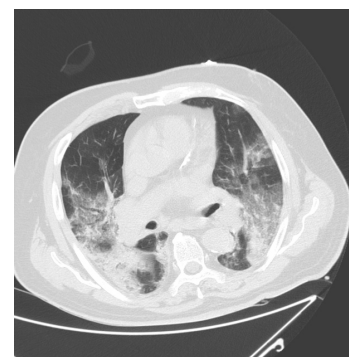COVID-19 pathogenesis



ACE2 receptor on
Pulmonary epithelium
& endothelium

Asymptomatic
Minor infection
7-10 days fever &/or flu-like symptoms
anosmia

In a minority (5%)
COVID-19 pneumonia
Massive inflammatory response
Cytokine storm/macrophage activation



Moderate
(needs O2)

Severe
(needs mechanical
Ventilation)

Prothrombotic state due to effects of IL1, IL-6

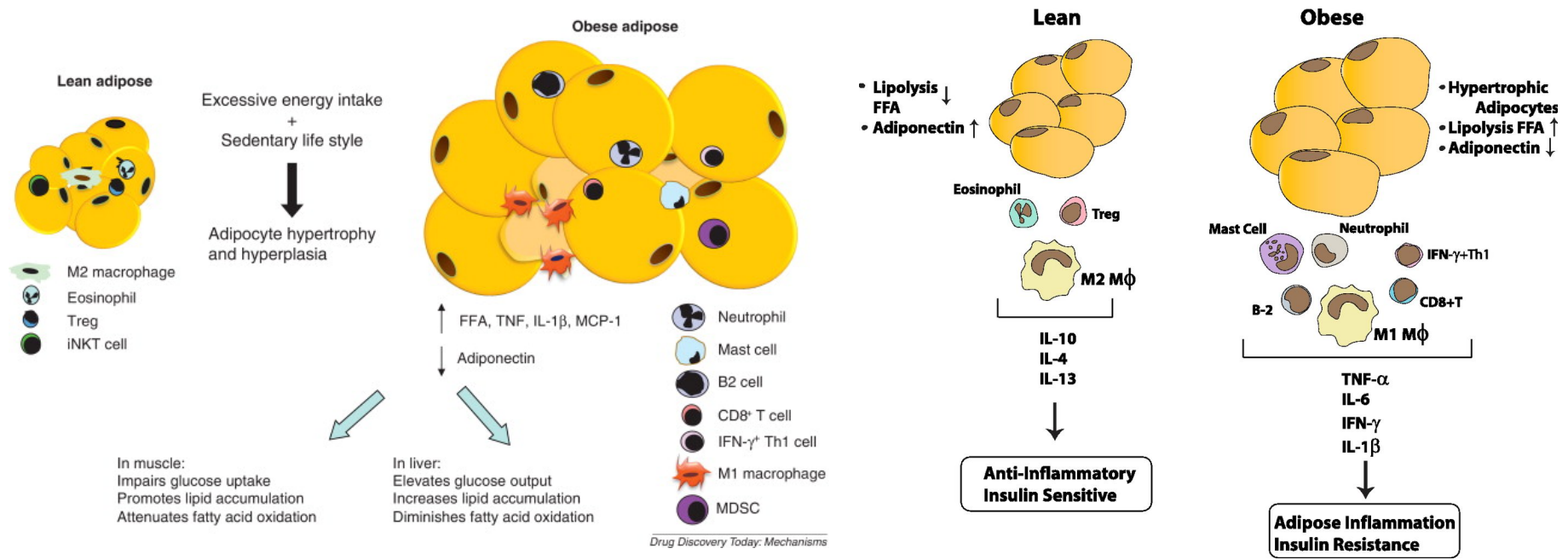
Does a pre-existing inflammatory state
make COVID-19 pneumonia more likely?
e.g atherosclerosis, diabetes, obesity ?



WORLD THROMBOSIS DAY
13 OCTOBER

Obesity is common: BMI > 25 in 75% of UK patients with severe COVID-19 infection (Source @ICNARC)

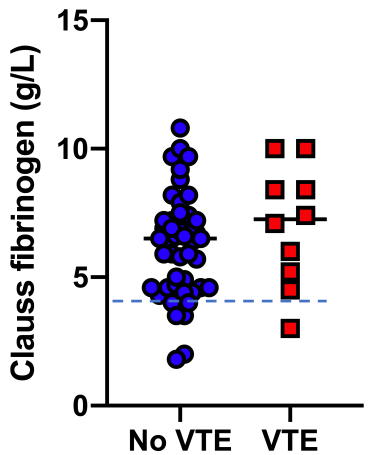
Hypertrophic adipocytes (like atherosclerosis & diabetes) induce an inflammatory state



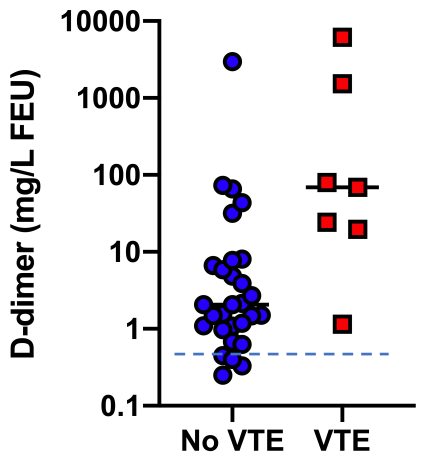
Coagulation and inflammation markers in 66 ICU patients with COVID-19

Desborough et al. Thrombosis Research preprint

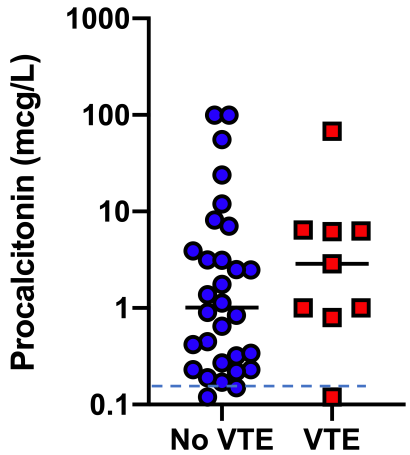
Clauss Fibrinogen



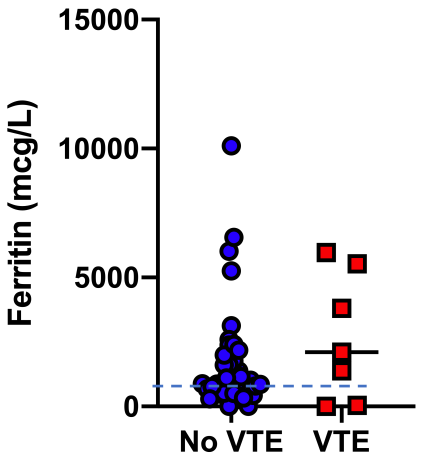
D-dimer



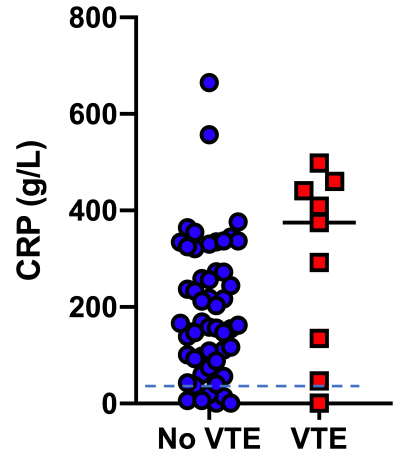
Procalcitonin



Ferritin



CRP



Dashed line is normal range

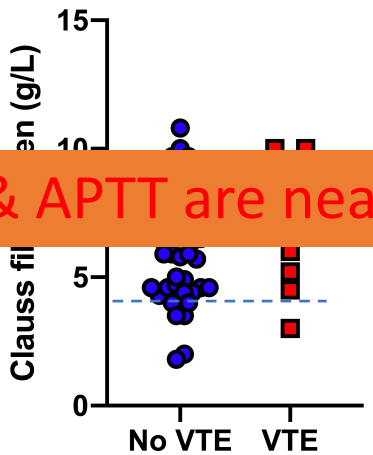


Coagulation and inflammation markers in 66 ICU patients with COVID-19

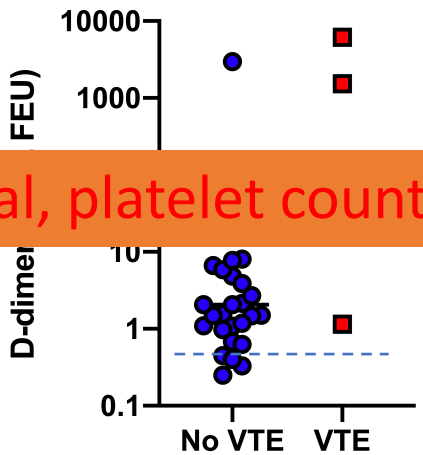
Desborough et al. Thrombosis Research preprint

This is not DIC! PT & APTT are near normal, platelet counts high normal

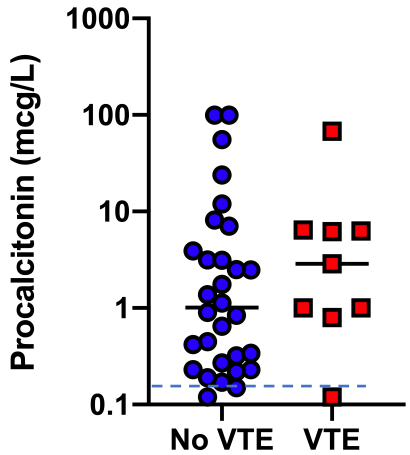
Clauss Fibrinogen



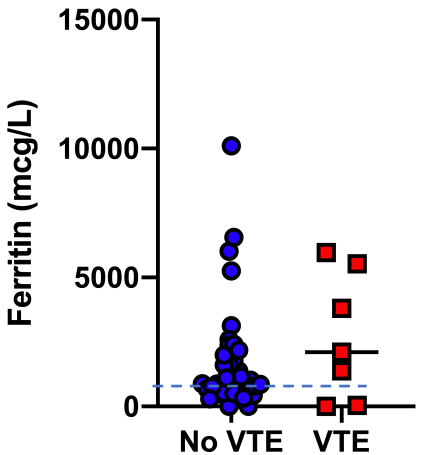
D-dimer



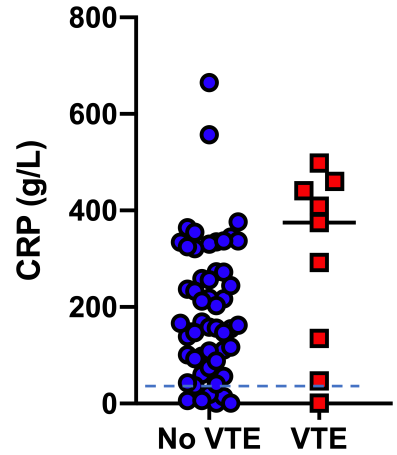
Procalcitonin



Ferritin

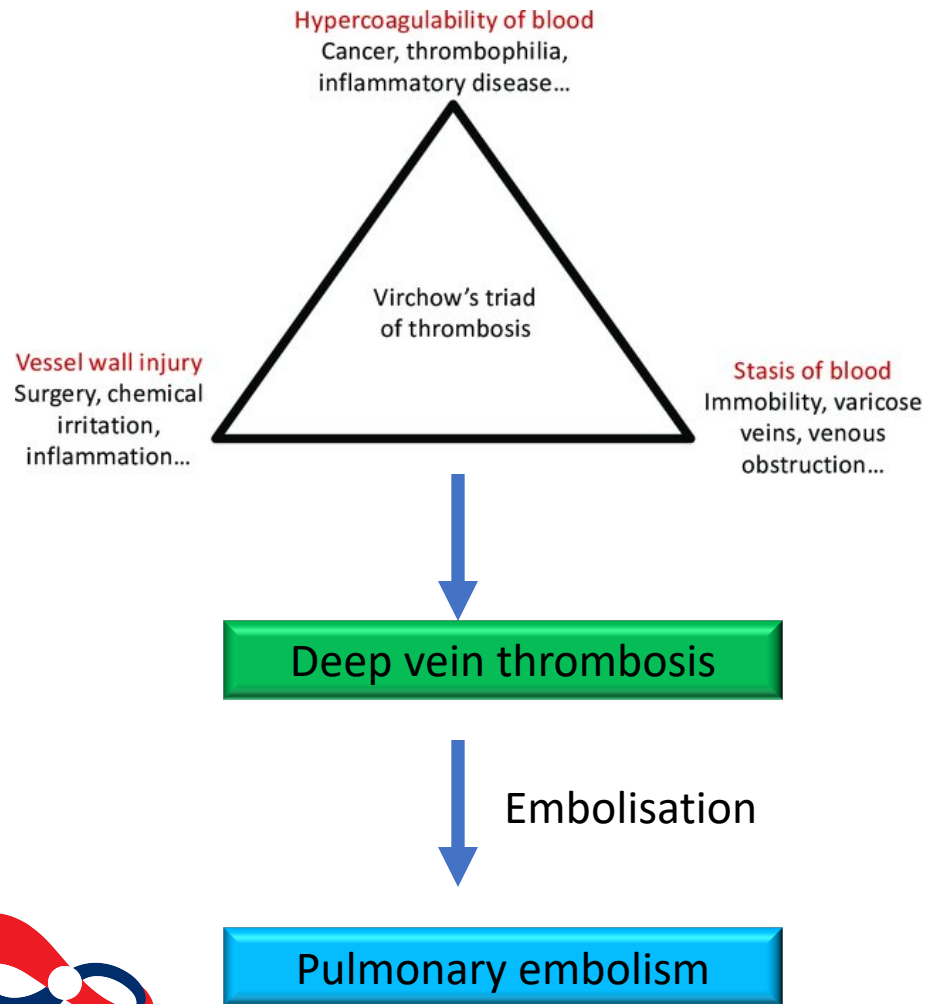


CRP

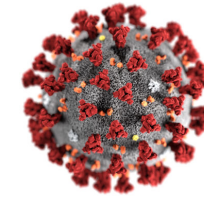


Dashed line is normal range

Lung thromboembolism in COVID-19 pneumonia



Immunothrombosis



COVID-19
pneumonia

